

# Double-Stage Complete Removal of Dumbbell-Shaped Trigeminal Schwannoma: 3-Dimensional Operative Video

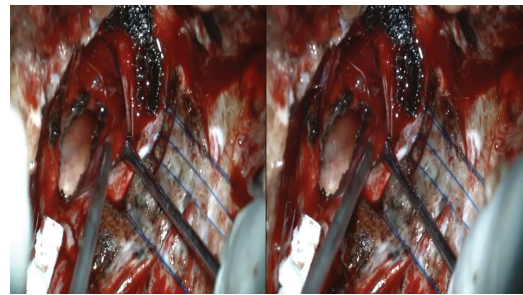
Alvaro Campero, MD, PhD\*<sup>‡</sup>, Matías Baldoncini, MD<sup>§</sup>,  
Guillermo Román, MD<sup>||</sup>, Juan F. Villalonga, MD\*<sup>‡</sup>

\*LINT, Facultad de Medicina, Universidad Nacional de Tucumán, Tucumán, Argentina;

<sup>‡</sup>Department of Neurological Surgery, Hospital Padilla, Tucumán, Argentina;

<sup>§</sup>Department of Neurological Surgery, Hospital San Fernando, Buenos Aires, Argentina;

<sup>¶</sup>Laboratory of Microsurgical Neuroanatomy, School of Medicine, University of Buenos Aires, Buenos Aires, Argentina; <sup>||</sup>Department of Neurological Surgery, Hospital Cullen, Santa Fe, Argentina



Watch now at <https://academic.oup.com/ons/article-lookup/doi/10.1093/ons/opab062>

**Correspondence:** Matías Baldoncini, MD, Department of Neurological Surgery, Jorge Luis Borges 2240, Floor 4, Buenos Aires 1425, Argentina. Email: [drbaldoncinimatias@gmail.com](mailto:drbaldoncinimatias@gmail.com)

© Congress of Neurological Surgeons 2021. All rights reserved. For permissions, please e-mail: [journals.permissions@oup.com](mailto:journals.permissions@oup.com)

Intracranial trigeminal schwannomas are rare tumors.<sup>1-4</sup> The aim of this 3-dimensional operative video is to present a double stage complete removal of a dumbbell-shaped trigeminal schwannoma.

This is a 25-yr-old male with headaches, diplopia, and facial pain. The MRI shows a big tumor located at the level of the cerebellopontine angle, petroclival region, and middle fossa. Because of the size of the tumor and its growth within the cerebellopontine angle, we decided to operate the patient in two stages. For the first surgery, the patient was in a semi-sitting position, and a retrosigmoid approach was performed. The second surgery was performed 2 mo after the first operation in a supine position for a pretemporal transzygomatic

approach. The pathological study was reported as a schwannoma, and the histological findings were spindle cell lesion with a storiform pattern and histiocytes.

The patient evolved without neurological deficit after the surgeries, and the postoperative MRI shows a complete resection of the tumor.

The patient gave the consent to use the images and surgical video.

Preoperative imaging plays an important role in diagnosis and surgical planning.<sup>3-6</sup> For these cases of trigeminal schwannomas with a large extension in the posterior fossa and middle fossa, we believe that the most prudent thing is to perform the surgery in 2 stages.<sup>3</sup>

**KEY WORDS:** Dumbbell-shaped schwannoma, Microsurgery, Skull base, Double-stage surgery

*Operative Neurosurgery* 0:1, 2021

DOI:10.1093/ons/opab062

Received, August 12, 2020. Accepted, December 25, 2020.

## Funding

This study did not receive any funding or financial support.

## Disclosures

The authors have no personal, financial, or institutional interest in any of the drugs, materials, or devices described in this article.

## REFERENCES

1. Agarwal A. Intracranial trigeminal schwannoma. *Neuroradiol J*. 2015;28(1):35-41.

2. MacNally SP, Rutherford SA, Ramsden RT, Evans DG, King AT. Trigeminal schwannomas. *Br J Neurosurg*. 2008;22(6):729-738.

3. Goel A, Muzumdar D, Raman C. Trigeminal neuroma: analysis of surgical experience with 73 cases. *Neurosurgery*. 2003;52(4):783-790.

4. Doddamani RS, Meena RK, Mohan SM, Venkatramana NK. Single stage complete removal of dumbbell trigeminal schwannoma in a child by skull base approach. *Asian J Neurosurg*. 2018;13(1):136-139.

5. Sharma BS, Ahmad FU, Chandra PS, Mahapatra AK. Trigeminal schwannomas: experience with 68 cases. *J Clin Neurosci*. 2008;15(7):738-743.

6. McCormick PC, Bello JA, Post KD. Trigeminal schwannoma. *J Neurosurg*. 1988;69(6):850-860.