


Contents lists available at [ScienceDirect](https://www.sciencedirect.com)

Interdisciplinary Neurosurgery: Advanced Techniques and Case Management

journal homepage: www.elsevier.com/locate/inat

Technical notes & surgical techniques



Intradural clinoidectomy for clipping left paraclinoid aneurysm: Three-dimensional operative video

Alvaro Campero^{a,b}, Matías Baldoncini^{c,d,*}, Juan F. Villalonga^{a,b}^a LINT, Facultad de Medicina, Universidad Nacional de Tucumán, Tucumán, Argentina^b Department of Neurological Surgery, Hospital Padilla, Tucumán, Argentina^c Laboratory of Microsurgical Neuroanatomy, Second Chair of Gross Anatomy, School of Medicine, University of Buenos Aires, Argentina^d Department of Neurosurgery, San Fernando Hospital, Buenos Aires, Argentina

ARTICLE INFO

Keywords:

Paraclinoid aneurysm
Skull base
Intradural clinoidectomy

ABSTRACT

Paraclinoid aneurysms represent a true microsurgical challenge for resolution [1,2] due to the proximity with neurovascular structures of the skull base [3–5]. We present a case: a 42-year-old woman with headache, detecting left paraclinoid aneurysm in angiography. A left pterional approach plus exposure of the internal carotid at the cervical level were performed. Also, an arciform durotomy with the opening of the sylvian fissure to the carotid cistern, were done. The anterior clinoid process was exposed, observing the aneurysm originating from the clinoid segment of the carotid artery, being impossible the clipping without anterior clinoidectomy [4,5]. The dura was cut medially from the optic canal to the clinoid process. Drilling was performed at the base of the clinoid process to expose the distal carotid dural ring.

The carotid was released in the clinoid segment through the section of the distal dural ring to mobilize it. After identifying the distal and proximal neck of the aneurysm, the reconstruction was started by placing a 90 degrees clip in the anteroposterior direction; then, a second clip in the posteroanterior direction and puncturing the aneurysm, showing that the aneurysmal flow is present. A third and fourth clip, were placed in tandem from the proximity to the internal carotid to the dome of the aneurysm. Finally, a fifth curved clip was placed on the previous ones to give them greater closing pressure. Postoperative angiography shows a complete exclusion of the aneurysm with adequate carotid permeability. The postoperative period was excellent, without any neurological deficit. The patient consented with publication of her images and videos.

Video 1

* Corresponding author at: Jorge Luis Borges, 4 Floor, 31 Department, Buenos Aires Postal Code: 1425, Argentina.

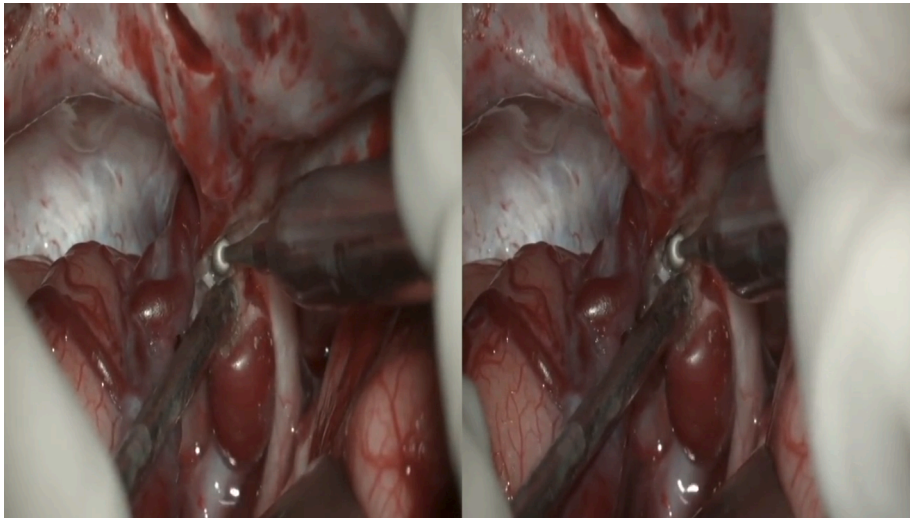
E-mail address: drbaldoncinimatias@gmail.com (M. Baldoncini).

<https://doi.org/10.1016/j.inat.2022.101542>

Received 5 March 2022; Accepted 14 March 2022

Available online 1 April 2022

2214-7519/© 2022 The Author(s). Published by Elsevier B.V. This is an open access article under the CC BY-NC-ND license (<http://creativecommons.org/licenses/by-nc-nd/4.0/>).



Video 1.

Submission Statement: The contents of this Video have not been copyrighted or published previously.

Funding Source: This research did not receive any specific grant from funding agencies in the public, commercial, or not-for-profit sectors.

Financial Disclosure: No.

Declaration of Competing Interest

The authors declare the following financial interests/personal relationships which may be considered as potential competing interests: The authors report no conflict of interest concerning the materials or methods used in this Surgical Video. We confirm that the video and manuscript has been read and approved by all named authors and that there are no other persons who satisfied the criteria for authorship but are not listed. We further confirm that the order of authors listed in the manuscript has been approved by all of us. We confirm that we have given due consideration to the protection of intellectual property associated with this work and that there are no impediments to publication.

We understand that the Corresponding Author is the sole contact for the Editorial process (including Editorial Manager and direct communications with the office). I am responsible for communicating with the other authors about progress, submissions of revisions and final approval of proofs. We confirm that we have provided a current, correct email address which is accessible by the Corresponding Author.

Bibliography

- [1] H.H. Batjer, T.A. Kopitnik, C.A. Giller, D.S. Samson, Surgery for paraclinoid carotid artery aneurysms, *J. Neurosurg.* 80 (1994) 650–658.
- [2] M. Guthikonda, F.G. Diaz, Surgical management of paraclinoid carotid aneurysms, *Neurosurgical Operative Atlas*, Park Ridge, IL, 1999, pp. 1–12.
- [3] H. Gibo, C. Lenkey, A.L.J. Rhoton, Microsurgical anatomy of the supraclinoid portion of the internal carotid artery, *J. Neurosurg.* 55 (1981) 560–574.
- [4] G.G. Ferguson, C.G. Drake, Carotid–ophthalmic aneurysms: the surgical management of those cases presenting with compression of the optic nerves and chiasm alone, *Clin. Neurosurg.* 27 (1980) 263–307.
- [5] E. Knosp, G. Muller, A. Perneczky, The paraclinoid carotid artery: anatomical aspects of a microneurosurgical approach, *Neurosurgery.* 22 (1988) 896–901.