

## Head-Mounted Augmented Reality in the Planning of Cerebrovascular Neurosurgical Procedures: A Single-Center Initial Experience

Matias Costa<sup>1</sup>, Clifford Pierre<sup>1</sup>, Juan Vivanco-Suarez<sup>1</sup>, Matias Baldoncini<sup>2</sup>, Zane Tymchak<sup>1</sup>, Akshal Patel<sup>1</sup>, Stephen J. Monteith<sup>1</sup>

■ **BACKGROUND:** Augmented reality (AR) technology has played an increasing role in cerebrovascular neurosurgery over the last 2 decades. Hence, we aim to evaluate the technical and educational value of head-mounted AR in cerebrovascular procedures.

■ **METHODS:** This is a single-center retrospective study of patients who underwent open surgery for cranial and spinal cerebrovascular lesions between April and August 2022. In all cases, the Medivis Surgical AR platform and HoloLens 2 were used for preoperative and intraoperative (preincision) planning. Surgical plan adjustment due to the use of head-mounted AR and subjective educational value of the tool were recorded.

■ **RESULTS:** A total of 33 patients and 35 cerebrovascular neurosurgical procedures were analyzed. Procedures included 12 intracranial aneurysm clippings, 6 brain and 1 spinal arteriovenous malformation resections, 2 cranial dural arteriovenous fistula obliterations, 3 carotid endarterectomies, two extracranial-intracranial direct bypasses, two encephaloduroangiosynostosis for Moyamoya disease, 1 biopsy of the superficial temporal artery, 2 microvascular decompressions, 2 cavernoma resections, 1 combined intracranial aneurysm clipping and encephaloduroangiosynostosis for Moyamoya disease, and 1 percutaneous feeder catheterization for arteriovenous

malformation embolization. Minor changes in the surgical plan were recorded in 16 of 35 procedures (45.7%). Subjective educational value was scored as “very helpful” for cranial, spinal arteriovenous malformations, and carotid endarterectomies; “helpful” for intracranial aneurysm, dural arteriovenous fistulas, direct bypass, encephaloduroangiosynostosis, and superficial temporal artery-biopsy; and “not helpful” for cavernoma resection and microvascular decompression.

■ **CONCLUSIONS:** Head-mounted AR can be used in cerebrovascular neurosurgery as an adjunctive tool that might influence surgical strategy, enable 3-dimensional understanding of complex anatomy, and provide great educational value in selected cases.

### INTRODUCTION

Cerebrovascular neurosurgery requires ultimate precision and a thorough understanding of complex neurovascular anatomy. The evolution of the discipline has been guided by improved technologies such as surgical microscopes, intraoperative angiography with fluorescein or indocyanine green, and catheter-based cerebral angiography.

#### Key words

- Augmented reality
- Cerebrovascular
- Neurosurgery
- Technology

#### Abbreviations and Acronyms

- 3D:** 3-dimension  
**AN:** Attending neurosurgeon  
**AR:** Augmented reality  
**AVM:** Arteriovenous malformation  
**CEA:** Carotid endarterectomy  
**CF:** Cerebrovascular fellows  
**CTA:** Computed tomography angiography  
**DAVF:** Dural arteriovenous fistula  
**Dyna CTA:** Cone-beam CTA

**HMAR:** Head-mounted AR

**IA:** Intracranial aneurysms

**VR:** Virtual reality

From the <sup>1</sup>Cerebrovascular Neurosurgery, Swedish Neuroscience Institute, Swedish Medical Center, Seattle, Washington, USA; and <sup>2</sup>Department of Neurological Surgery, Hospital San Fernando, Argentina

To whom correspondence should be addressed: Matias Costa, M.D.  
[E-mail: matiascostamd@gmail.com]

Citation: *World Neurosurg.* (2023).

<https://doi.org/10.1016/j.wneu.2022.12.086>

Journal homepage: [www.journals.elsevier.com/world-neurosurgery](http://www.journals.elsevier.com/world-neurosurgery)

Available online: [www.sciencedirect.com](http://www.sciencedirect.com)

1878-8750/\$ - see front matter © 2022 Elsevier Inc. All rights reserved.

Over the last quarter century, several publications have shown how the introduction of technologies such as virtual reality (VR), augmented reality (AR), and mixed reality has contributed to the development of technical milestones for the performance of complex cerebrovascular procedures.<sup>1</sup> Furthermore, currently available literature has focused on the utility of digital overlays using the surgical microscope.<sup>1-16</sup> To our knowledge, this is the first report of a case series of patients who underwent cerebrovascular neurosurgical procedures with the use of a head-mounted AR (HMAR) system.

## METHODS

### Patient Selection

We retrospectively analyzed all patients who underwent open surgery for the treatment of cerebrovascular lesions between April 1 and August 31, 2022. The local institutional review board approved this retrospective cohort study at the participating center. Consent to participate was waived because of the retrospective nature of this study. Procedural consent was obtained from each patient or a legally authorized representative and all patients consented to the publication of his/her image. All cerebrovascular cases where AR technology was used for preoperative and intraoperative planning were selected. The use of AR in the intraoperative setting was limited to the preincision stage. The technology was not used during the surgical procedure. This case series has been reported in line with the PROCESS Guideline.<sup>17</sup>

### Imaging Acquisition and Processing

All patients underwent preoperative imaging according to the pathology being treated. Studies included head computed tomography, computed tomography angiography (CTA), magnetic resonance angiography, magnetic resonance imaging, cerebral

angiography, spinal angiography, and cone-beam CTA (Dyna CTA).

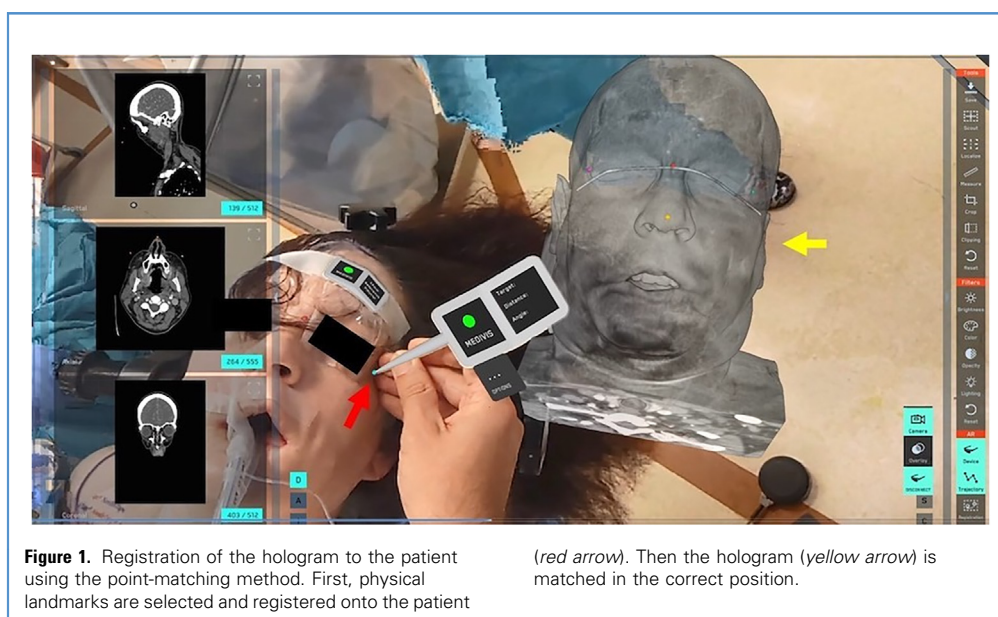
The Medivis Surgical AR workstation (Medivis, New York, NY) was connected to the Picture Archived Communication System, and the selected patient images were uploaded. The HoloLens 2 (Microsoft, Redmond, WA) was then linked to the AR workstation. The uploaded images were processed as needed using functions such as coloring, windowing, cropping, filtering, and brightening while visualizing the hologram in 3-dimensions (3D). The original and postprocessed versions of the images were stored in the platform to be available for use in the operating room.

### Hologram-Patient Registration

The use of the AR system in real-time depends on the configuration to match the hologram image to the patient. There are 2 methods to match the hologram. The first is the holographic point-matching registration, performed with an optical localizer tool recognized by the HoloLens 2. This method works by matching and coregistering physical landmark points on the patient's head with virtual fiducial points in the hologram image (Figure 1). The second is free-hand registration which is performed using surface anatomy. The matching is completed using hand gestures (recognized by the HoloLens 2) to accurately adapt the hologram's position and size to align with the patient's head. The selection between the techniques was made according to each case with the goal of obtaining optimal registration, function, and accuracy (Figure 2).

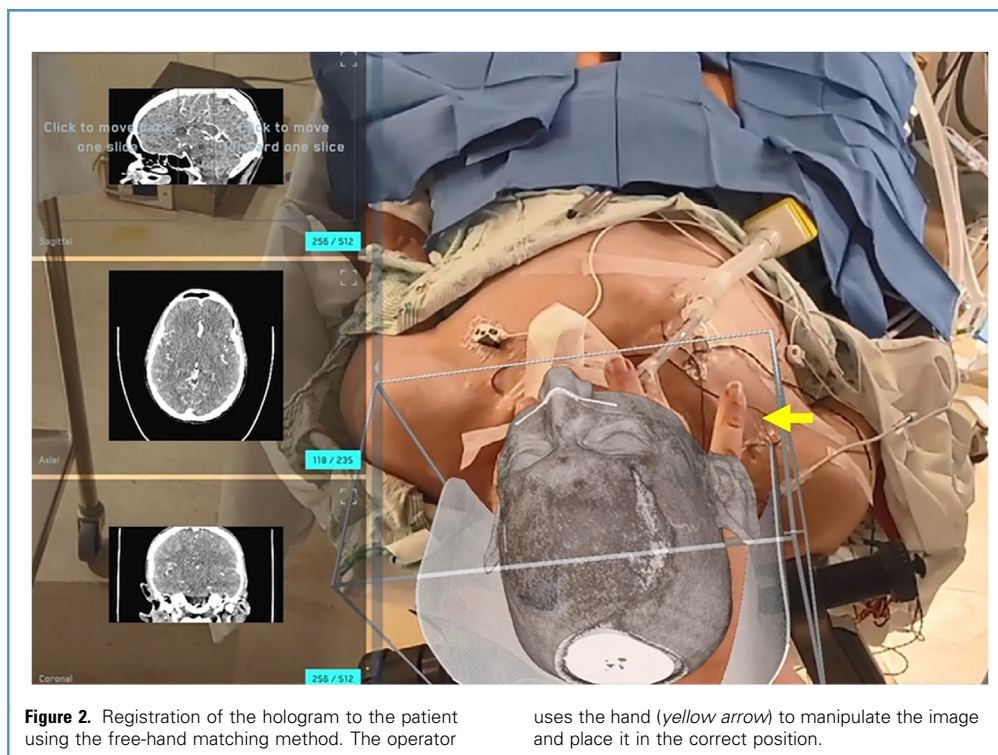
### AR-Assisted Surgical Strategy Planning

The AR system was used to evaluate the 3D-rendered reconstruction of the imaging studies of the case at the clinic visit and in the operating room. The cerebrovascular neurosurgeon planned the skin incision in the standard fashion utilizing routine Stealth



**Figure 1.** Registration of the hologram to the patient using the point-matching method. First, physical landmarks are selected and registered onto the patient

(red arrow). Then the hologram (yellow arrow) is matched in the correct position.



**Figure 2.** Registration of the hologram to the patient using the free-hand matching method. The operator

uses the hand (yellow arrow) to manipulate the image and place it in the correct position.

neuronavigation (Medtronic, Inc., Louisville, CO) when appropriate. Simultaneously, the matching configuration of the hologram image was performed. We verified that the holographic registration was accurate by using classical anatomical landmarks. Head and neck position, bed height, skin incision site, and other relevant aspects were adjusted accordingly and always verified by Stealth navigation, which is approved by the United States Food and Drug Administration. One neurosurgeon performed the registration and verification steps using the HoloLens 2. The remaining surgical team members visualized the AR image reproduced on a separate visual monitor. The surgical team presented and discussed relevant recommendations for the surgical treatment plan.

### Objective Value Analysis

Each patient underwent a 2-step pathway during the surgical decision process. The first stage included the traditional pathway utilizing conventional imaging modalities such as CTA, magnetic resonance imaging/magnetic resonance angiography, brain or spine angiography, and optical or magnetic 2-dimensional wand-based Stealth neuronavigation. The second stage was the surgical planning after preoperative and intraoperative team analysis of the pathology using the AR system. The differences between the conventional plan and AR-assisted plan were recorded and classified as no changes, minor changes, or major changes. Minor changes were defined as the addition or subtraction of surgical steps without modifying the surgical goal, approach, or side (laterality) of the approach. Major changes represented variations in the surgical goal, approach, or side (laterality) of the approach.

Clinical patient outcomes were defined by the modified Rankin scale at the 1-month follow-up. Surgical technical outcomes were also outlined when applicable.

### Subjective Value Analysis

The following aspects defined the educational value of the AR technology: (1) the system's capacity to promote further understanding of the normal, pathological, and surgical anatomy specific to the patient and (2) improved understanding of the surgical steps and technical nuances of the procedure. In addition, attending neurosurgeons (ANs) and cerebrovascular fellows (CFs) categorized the educational value into 1 of 3 categories "not helpful," "helpful," and "very helpful."

### RESULTS

The analysis included 33 patients who underwent the following 35 cerebrovascular neurosurgical procedures (Table 1): 12 cases of clipping for intracranial aneurysms (IAs) (Figure 3), 6 resections of intracranial arteriovenous malformations (AVMs) (Figures 4 and 5), 2 microvascular decompressions for trigeminal neuralgia, 2 obliterations of intracranial dural arteriovenous fistulae (DAVFs), 3 carotid endarterectomies (CEAs) (Figure 6), 2 encephaloduroangiosynostosis for Moyamoya disease (Figure 7), 2 extracranial-intracranial direct bypasses for Moyamoya disease, 1 combined IA clipping and encephaloduroangiosynostosis for Moyamoya disease, 1 resection of spinal cord AVM (Figure 8), 2 resections of cavernoma (inferior cerebellar peduncle and occipital lobe), 1 bilateral superficial temporal artery biopsy for

**Table 1.** Baseline and Procedural Characteristics of Cases Using Head-Mounted Augmented Reality Assistance

Case No.	Age/ Sex	Procedure	Preop. mRS	1-month Postop. mRS/Surgical Outcome	Registration Method	AR Image Source	Surgical Plan Modifications upon AR-Hologram Evaluation	Other Perceived Benefits/Limitations	Educational Value
1	52/F	Ruptured MCA M1 IA clipping	4	2/no residual neck	Free hand	CTA	Correct preop clip selection; head rotation adjusted	3D visualization of the parent vessel, aneurysm neck, en-passage branches, and MCA M2s takeoff/parenchyma required filtering because blood blocked complete vessel visualization	Helpful
2	49/F	Unruptured MCA M1-M2 IA clipping	0	0/no residual neck	Both	CTA	None		Helpful
3	41/F	Unruptured MCA M1-M2 IA clipping	1	0/no residual neck	Free hand	CTA	None	3D visualization of the parent vessel, aneurysm neck, en-passage branches, and MCA M2s takeoff/Sylvian veins less visible	Helpful
4	68/F	Unruptured MCA M1-M2 IA clipping	2	1/no residual neck	Free hand	CTA	Preop clip selection was accurate		Helpful
5	63/F	Unruptured MCA M1-M2 IA clipping	1	2/no residual neck	Free hand	CTA	None		Helpful
6	76/F	Unruptured MCA M1-M2 IA clipping	0	1/no residual neck	Both	CTA	None		Helpful
7	72/F	Ruptured MCA M1-M2 IA clipping	3	1/no residual neck	Both	CTA Dyna CTA	Preop clip selection was accurate		Helpful
8	51/F	Unruptured AComm IA clipping	1	0/no residual neck	Both	CTA	Improved head rotation to optimize visualization of both ACA A2s in the surgical corridor	Clear visualization of AComm complex with both lobes of aneurysm visible; clear visualization of ACA A2s and Heubner due to optimized head rotation angle	Helpful
9	78/F	Unruptured AComm IA clipping	1	0/no residual neck	Both	CTA		3D visualization of both ACA (A1s, A2s), AComm, aneurysm neck, and en-passage arteries; anterior cranial fossa floor and anterior clinoid processes very clearly seen in relation to the angle of attack of the aneurysm neck	Helpful
10	62/ M	Unruptured Acomm IA clipping	1	1/no residual neck	Both	CTA	None		Helpful
11	39/ M	Unruptured Acomm IA clipping	1	0/no residual neck	Both	CTA	Improved head rotation to optimize visualization of both ACA A2s in the surgical corridor	3D visualization of both ACA (A1s, A2s), AComm, aneurysm neck, and en-passage arteries; anterior cranial fossa floor and anterior clinoid processes very clearly seen in relation to the angle of attack of the aneurysm neck	Helpful

12	48/F	Bilateral ICA terminus IA clipping, right side ruptured	3	2/no residual necks	HPM	CTA Dyna CTA	Head rotation was changed to avoid the overlap of the ipsilateral clip with the contralateral crosscourt approach to reach the contralateral aneurysm; preop clip selection was accurate	Exact parent vessels and aneurysm morphology as seen intraoperative	Helpful
13	64/ M	Temporal SM3 AVM resection	2	1/no residual AVM	Both	CTA Dyna CTA MRA	None	Holographic Dyna CTA provided extraordinary arterial and venous 3D anatomic display; improved surgical strategy and localization of feeding vessels and draining veins	Very helpful
14	55/ M	Parieto-occipital SM3 AVM resection	2	0/no residual AVM	Both	CTA Dyna CTA MRA	Head lateral tilt modified	Surface localization of draining vein and big MCA feeder that allowed early resection; Dyna CTA showed extraordinary arterial and venous 3D anatomic display	Very helpful
15	28/ M	Parietal SM4 AVM + Flow related IA resection	3	1/no AVM or residual aneurysm	Free hand	CTA Dyna CTA MRA	None	Surgical trajectory and clot evacuation was optimized; feeder arteries, nidus, flow-related aneurysm, and draining veins are visible as encountered during surgery; Dyna CTA showed extraordinary arterial and venous 3D anatomic display	Very helpful
16	22/ M	Ruptured left occipital SM2 AVM resection	4	2/no residual AVM	Free hand	CTA Dyna CTA MRA	None	Visualization of hematoma drainage site besides AVM; intuitive tracking of draining vein; Dyna CTA showed extraordinary arterial and venous 3D anatomic display	Very helpful
17	50/ M	Ruptured left parietal SM4 AVM resection	5	3/no residual AVM	Free hand	CTA Dyna CTA MRA	None	Visualization of draining vein, SSS, and feeding vessels; hologram significantly improved the understanding of the 3D location of feeding arteries and draining veins; optimization of surgical attack angles	Very helpful
18	49/ M	Left prefrontal SM5 AVM, percutaneous puncture with embolization of MMA feeder	3	2/AVM downstaged, diminished vascular steal to left hemisphere, improved motor symptoms.	Both	CTA Dyna CTA MRA	Minimal craniotomy performed over largest AVM feeder (MMA) and direct puncture; visualization of superficial draining vein continuously under the bone	Precise marking of the full extension of the straightest segment of the MMA (suitable for direct stick and sheath placement) was marked precisely in its full extension.	Very helpful

3D, 3-dimension; ACA, anterior cerebral artery; AComm, anterior communicating artery; AR, augmented reality; AVM, arteriovenous malformation; CEA, carotid endarterectomy; CTA, computed tomography angiography; DAVF, dural arteriovenous fistula; Dyna CTA, cone-beam CTA; EDAS, encephaloduroarteriosynangiosis; F, female; HPM, hologram point-matching; IA, intracranial aneurysm; ICA, internal carotid artery; ICAD, intracranial atherosclerosis disease; ICP, inferior cerebellar peduncle; M, male; MCA, middle cerebral artery; MES, microembolic signals; MMA, middle meningeal artery; MMD, Moyamoya disease; MRA, magnetic resonance angiography; MRI, magnetic resonance imaging; mRS, modified Rankin Scale; MVD, microvascular decompression; OA, occipital artery; Postop., postoperative; Preop., preoperative; SM, Spetzler-Martin; SSS, superior sagittal sinus; STA, superficial temporal artery; US, ultrasound.

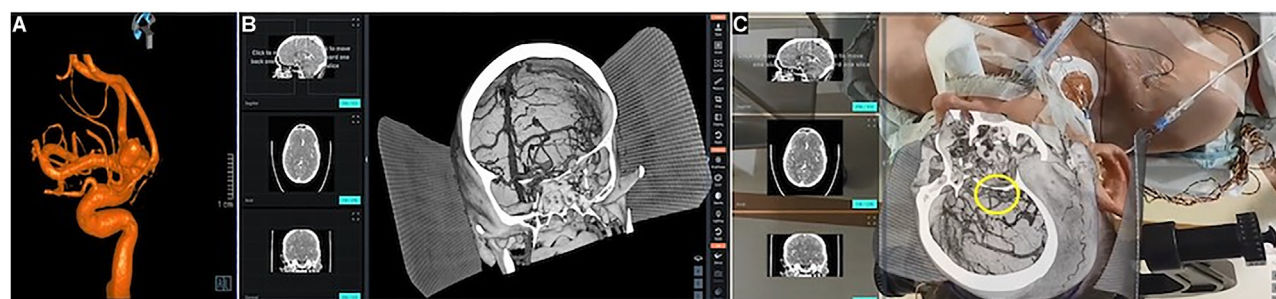
Continues

**Table 1.** Continued

Case No.	Age/ Sex	Procedure	Preop. mRS	1-month Postop. mRS/Surgical Outcome	Registration Method	AR Image Source	Surgical Plan Modifications upon AR-Hologram Evaluation	Other Perceived Benefits/ Limitations	Educational Value
19	64/ M	Borden 3 DAVF (MMA frontal branch to cortical vein) surgical obliteration	3	2/no residual DAVF	Both		View from inside the cranial cavity (inside-out) with precise location of the fistulous point through the contralateral side after cropping half of the skull; reduction of the access with a burr hole-sized opening over the fistulous point	Dyna CTA showed extraordinary arterial and venous 3D anatomy quality	Helpful
20	64/ M	Borden 3 DAVF (MMA parietal branch to cortical vein) surgical obliteration	3	2/no residual DAVF	Both	CTA Dyna CTA	Allowed the precise performance of a small sized craniotomy over fistulous point	Stealth-based assistance was insufficient to localize the branches of the MMA and draining veins; Dyna CTA showed extraordinary 3D anatomic display of the arteries and veins	Helpful
21	53/F	MVD for trigeminal neuralgia	2	0/pain free	Both	MRI	None	Optimal visualization of the petrous bone surface in relationship to the cerebellar petrosal surface; optimal visualization of the position of cranial nerves (V, VII, and VIII) to define the surgical working angles	Not helpful
22	83/ M	MVD for trigeminal neuralgia	1	0/pain free	Free hand	MRI	Adjusted head flexion		Not helpful
23	75/ M	CEA	1	1/good reperfusion, no MES	Free hand	Neck CTA	Allowed the performance of a smaller incision (compared to the standard approach) over the stenotic point	Precise location of the level of ICA stenosis; optimal visualization of surrounding structures (common carotid artery, external carotid artery, sternocleidomastoid muscle, mylohyoid muscle, omohyoid muscle, trachea, and esophagus)/cranial nerve XII is not visible	Very helpful
24	66/ M	CEA	2	1/good reperfusion, no MES	Free hand	Neck CTA			Very helpful
25	61/F	CEA	1	1/good reperfusion, no MES	HPM	CTA		Precise location of ICA stenosis level, CCA, ICA, ECA.	Very helpful
26	46/F	Direct STA-MCA bypass for MMD	2	2/graft patent	Both	CTA	Longer STA tracing compared to US Doppler; STA harvesting was completed without distal surgical "search"; efficient identification of the donor.	Inadequate visualization of MCA M4 branches due to inadequate image window setting (user error)	Helpful
27	50/ M	Direct STA-MCA bypass for MMD	2	2/graft patent	Both	CTA			Helpful
28	67/F	Right EDAS with STA for MMD and right MCA IA clipping	1	1/no perioperative ischemic events	Both	CTA			Helpful
29	40/ M	EDAS for ICAD	2	2/no perioperative ischemic events	HPM	MRA CTA			Helpful

30	48/F	Left EDAS with OA for MMD	2	2/no perioperative ischemic events	Both	CTA	Improved capacity to trace the occipital artery in its proximal (where the thickness of the tissue decreases US Doppler signals) and distal portions		Helpful
31	48/F	Right EDAS with OA for MMD	2	2/no perioperative ischemic events	HPM	CTA			Helpful
32	28/F	T12-L1 conus medullaris AVM resection	4	3/no residual AVM	Free hand	CTA Dyna CTA MRA	Allowed the performance of a 2-level instead of a 3-level	3D hologram image using Dyna CTA of the radicular branch reinforced surgeon's decision of a posterior spinal approach and improved the differentiation of pathologic versus normal vascular structures	Very helpful
33	78/M	Bilateral STA biopsies for temporal arteritis	1	0/successful biopsy	Free hand	CTA	None	Length of the trajectory of STA branches was superior compared to Doppler ultrasound (audio signal was lost before visual)	Helpful
34	37/F	Right ICP cavernoma resection	2	1/no residual cavernoma	Both	MRI	None	Improved orientation of the angle of the microscope in relation to patient's shoulder to reach target lesion	Not helpful
35	39/F	Occipital cavernoma resection	2	1/no residual cavernoma	HPM	MRI	None	Improved understanding of the surgical angle of attack to reach the lesion	Not helpful

3D, 3-dimension; ACA, anterior cerebral artery; AComm, anterior communicating artery; AR, augmented reality; AVM, arteriovenous malformation; CEA, carotid endarterectomy; CTA, computed tomography angiography; DAVF, dural arteriovenous fistula; Dyna CTA, cone-beam CTA; EDAS, encephaloduroarteriosynangiosis; F, female; HPM, hologram point-matching; IA, intracranial aneurysm; ICA, internal carotid artery; ICAD, intracranial atherosclerosis disease; ICP, inferior cerebellar peduncle; M, male; MCA, middle cerebral artery; MES, microembolic signals; MMA, middle meningeal artery; MMD, Moyamoya disease; MRA, magnetic resonance angiography; MRI, magnetic resonance imaging; mRS, modified Rankin Scale; MVD, microvascular decompression; OA, occipital artery; Postop., postoperative; Preop., preoperative; SM, Spetzler-Martin; SSS, superior sagittal sinus; STA, superficial temporal artery; US, ultrasound.



**Figure 3.** Case 10. The patient underwent clipping for an anterior communicating artery aneurysm ( $6.7 \times 8.1 \times 6.2$  mm). (A) 3D angiogram reconstruction shows the aneurysm before treatment. (B) Hologram image of the AR platform using the CTA of the head. (C) Operating room

view through the HoloLens 2 showing the hologram image matched to the patient with the target aneurysm and surrounding vessels in sight (yellow circle). AR, augmented reality; CTA, computed tomography angiogram; 3D, 3-dimensional.

temporal arteritis, and 1 percutaneous puncture and embolization of an AVM feeder. Holographic point-matching alone was performed in 5 (14%) procedures. Free-hand registration alone was used in 12 (34%) cases. A combination of holographic point-matching and free-hand registration was used in 18 (51%) cases. Minor changes in the surgical plan were recorded in 16 (46%) procedures. Subjective educational value was the following: “very helpful” for cranial and spinal AVMs and CEA; “helpful” for IA clipping, DAVFs, direct bypass, encephaloduroangiosynostosis, and superficial temporal artery biopsy; and “not helpful” for cavernoma resection and microvascular decompressions. We did not encounter user fatigue, disorientation, or headaches associated with the use of the HoloLens 2. There was no morbidity or mortality directly attributed to the use of AR technology.

## DISCUSSION

The current era of cerebrovascular neurosurgery offers innovative technologies such as AR, VR, and mixed reality that incorporate a 3D perspective for planning and performing procedures. The development of different platforms has allowed the superimposition of AR virtual content into the real world.<sup>1</sup> The projected hologram fused to the patient’s head can display information from different imaging modalities, providing a more intuitive surgical experience.<sup>2</sup> In contrast, VR immerses the user into a complete digital environment that obscures the physical world, which makes it more suitable for case simulations.<sup>1</sup>

The use of AR and VR in neurosurgery has grown particularly in spine surgery, neurosurgical training education, and specific procedures (tumor resection, brain abscesses, stereotactic procedures, and external ventricular drain insertion).<sup>4</sup> Some of the systems that allow the display of images using AR technology include the following: (1) heads-up display /microscope, (2) AR intraoperative brain imaging system, and (3) DEX-Ray system that overlays 3D images on a video stream.<sup>18</sup> Our series is the first to use a HMAR platform in cerebrovascular neurosurgery. The growth of this adjunct AR technology has impacted globally and across various medical specialties.<sup>3,5</sup> Based on our experience and previously published literature, we consider AR has the

potential to become a crucial educational element for neurosurgical training programs.<sup>3</sup> Although the subjective educational value obtained from AR is difficult to assess due to the paucity of “hard measuring points,” the overall utility of the technology can be meaningful and even guide the development of objective measuring tools. We agree with Ivan et al.<sup>19</sup> when they state that AR technology is not meant to replace a surgeon’s experience or the traditional navigation systems; in fact, its role is to create a 3D reconstruction of the patient’s normal and pathological structures.

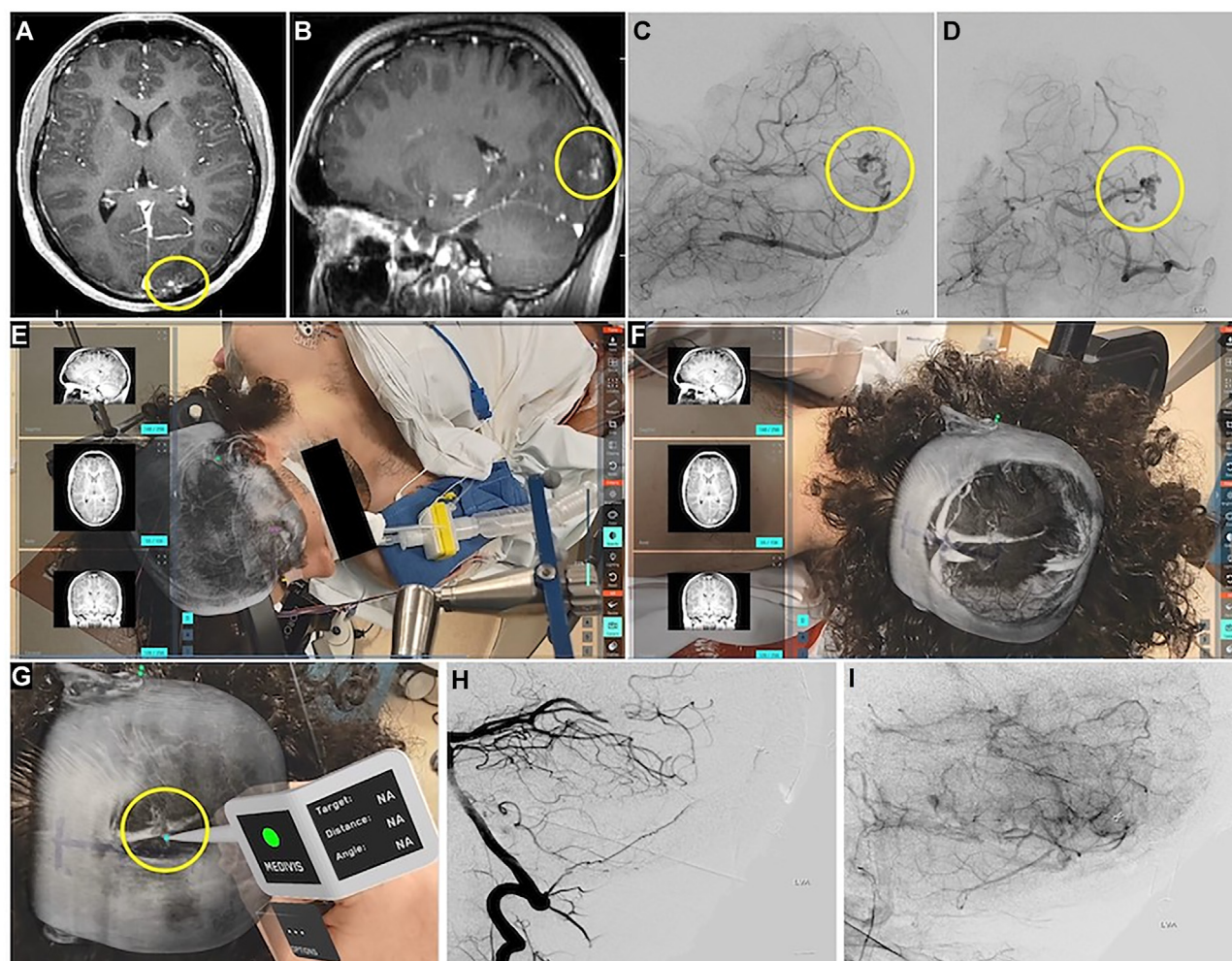
Most reports consider AR is useful for patient positioning, incision marking, and craniotomy planning. However, the use of the heads-up display/microscope systems to perform “macro” steps can be considered inconvenient by surgeons. On the other hand, the HMAR headset allows head positioning, incision, and craniotomy planning while avoiding the use of a microscope. Furthermore, most AR systems require cameras and monitors outside the line of sight of the surgical field, causing interruption in the workflow and adding complexity to the procedures.<sup>7,18,20</sup> In contrast, the HMAR system reduces interruptions and improves surgical fluency by avoiding the need to look away.

## HMAR for AVM Resection

Previous reports have argued that navigation accuracy and depth perception is negatively affected by brain shift while using AR (mainly heads-up display/microscope) for AVMs,<sup>21</sup> we acknowledge that this aspect most probably also affects HMAR navigation. In general, AVMs are challenging to evaluate from a 3D perspective. However, in this experience, we found that using the HMAR tool to evaluate the patient-specific anatomical characteristics in a 3D perspective offered a valuable spatial orientation and a better understanding of the surgical anatomy. Before the procedures, the hologram image of the AVMs was analyzed in highly magnified 360° views to identify relevant AVM morphology. Then, during the procedure, the hologram-patient registration feature was applied, and the pathology was revisited with the patient in position before the incision.

In cranial AVM cases, the relationship between the brain and the lesion can be challenging to integrate using 3D rotational





**Figure 4.** Case 16. The patient underwent resection of a left occipital AVM. Axial (A) and sagittal (B) views of the left occipital AVM with increased contrast enhancement (yellow circles) on magnetic resonance imaging of the head with gadolinium. Lateral (C) and anteroposterior (D) views of the diagnostic angiogram displaying the AVM with feeders from the left posterior cerebral artery and superficial venous drainage (yellow circles).

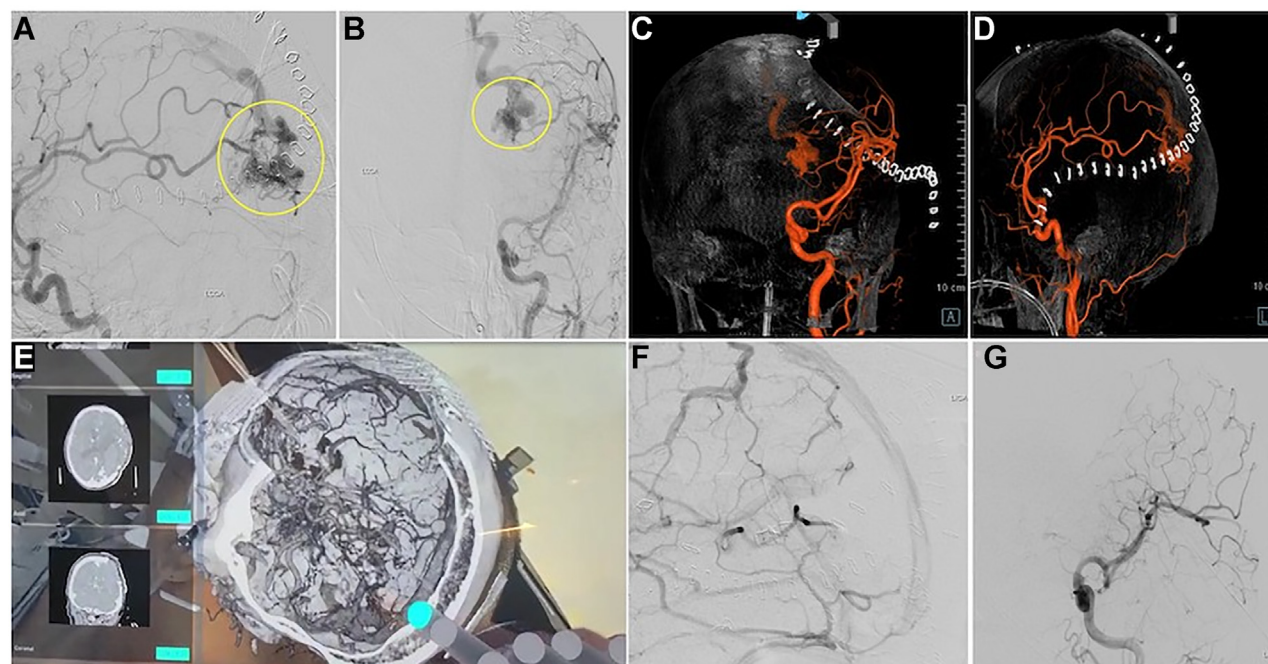
Lateral (E) and posterior (F) views of the hologram image in position. (G) The registration was performed with the point-matching method over the target lesion where the surgical incision was planned (yellow circle). Intraoperative diagnostic angiogram showing complete resection of the AVM in the lateral (H) and anteroposterior (I) views. AVM, arteriovenous malformation.

angiography. However, with the AR tool, it is possible to improve the anatomical orientation, which can potentially increase confidence and procedural safety while decreasing surgical times.<sup>1,22</sup> In these cases, ANs and CFs categorized the educational value of HMAR as “very helpful.”

Case 32 illustrates the utility of this tool in a patient who presented a complex medullary spinal AVM. The AR tool helped to minimize the laminectomy exposure and confirmed the precise location of the feeding vessels. Additionally, by placing the hologram image (from Dyna CTA) over the surgical view, the abnormal AVM vessels could be accurately identified and cauterized while preserving the nonpathological ones (Figure 8).

#### HMAR for IA Clipping

Six cases benefited from the use of HMAR by the identification of minor details that improved the head positioning and clip selection (size and shape). In all cases, the anatomical configuration of the aneurysms and the presence of any vascular anomalies were identified before the procedures (Figure 3). Our findings about the usefulness of the HMAR system are supported by previous reports which show similar results using different imaging systems.<sup>10,13,15,18</sup> Additionally, we found that the use of high-quality CTA, magnetic resonance angiography, or Dyna CTA for reconstructive imaging aids in visualizing specific vascular and parenchymal features associated with the overlying bony anatomy.



**Figure 5.** Case 14. The patient underwent resection of a left parietooccipital AVM. Lateral (A) and anteroposterior (B) views of the Spetzler-Martin Grade 3 AVM (yellow circles) on the diagnostic angiogram. 3D angiogram reconstruction of the AVM in anteroposterior (C) and lateral (D) views. (E) The hologram registration was performed

with point-matching and free-hand. Intraoperative diagnostic angiogram showing complete resection of the AVM in the lateral (F) and anteroposterior (G). AVM, arteriovenous malformation; 3D, 3-dimensional.

We believe that the ability to visualize head positioning, craniotomy size/location, aneurysm morphology, associated vessels, and clip direction (including the “landing zone”) can potentially decrease procedural times and improve the operator’s performance. In these cases, ANs and CFs categorized the educational value of HMAR as “helpful.”

#### HMAR for Direct and Indirect Bypasses

In cranial bypass surgery, AR offered a longer and more distal identification and tracing of the superficial temporal artery or the occipital artery compared to the visualization obtained with ultrasound Doppler. In contrast to previously reported series, we could not reliably identify the middle cerebral artery M4 segment recipient branches in the preoperative setting.<sup>4,8,14</sup> In these cases, ANs and CFs categorized the educational value of HMAR as “helpful.”

#### HMAR for DAVF Surgery

To our knowledge, only 1 AR-assisted cranial DAVF case has been described in the literature.<sup>20</sup> Of note, we included 2 cranial cases in which the feeder and draining vein (middle meningeal artery to pial veins in both) was readily identified through an inside-out view running over the internal surface of the calvaria. We were unable to define those vessels using classical neuronavigation. In both cases, AR allowed a precise burr hole approach and

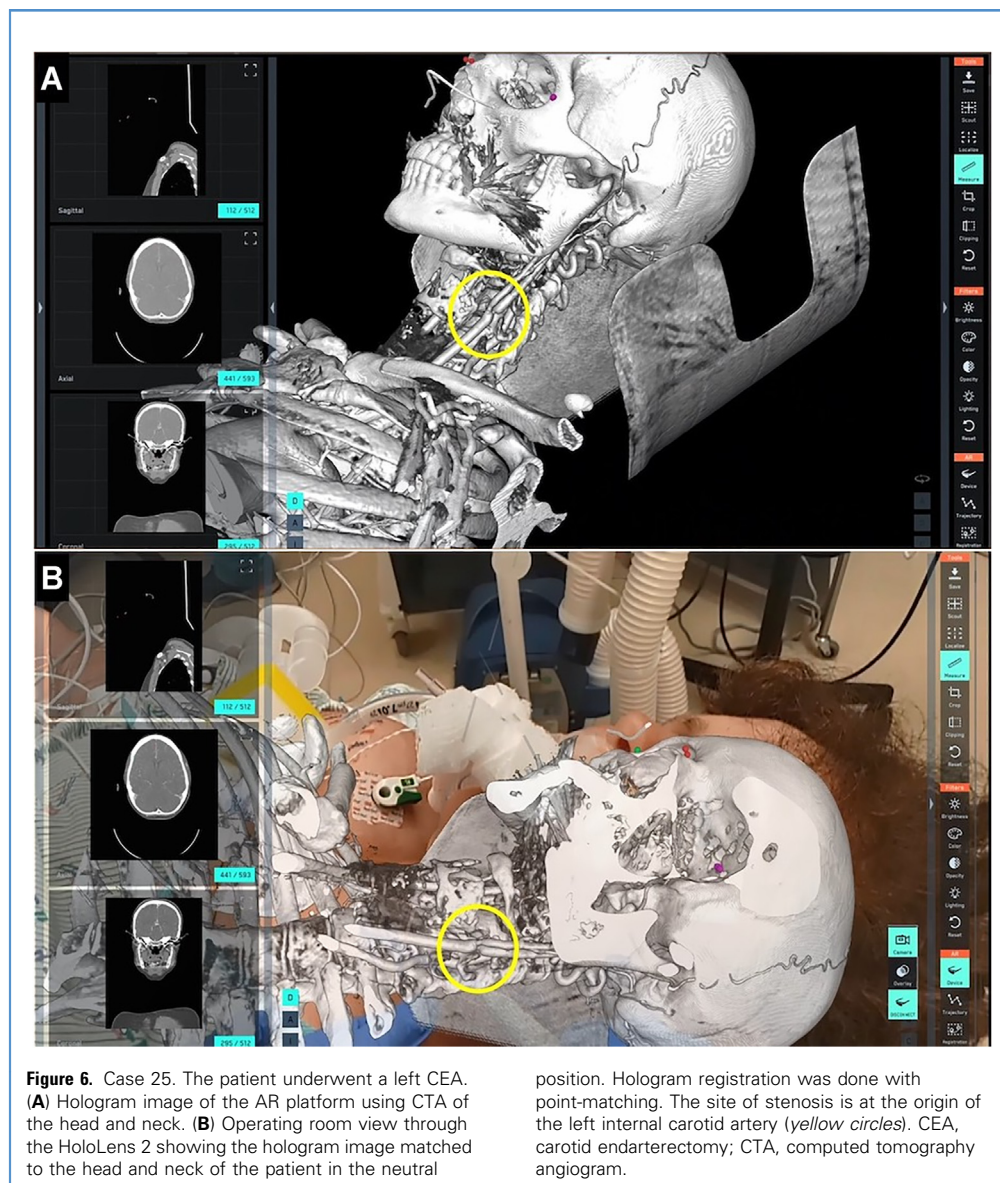
coagulation of the fistulous point. In these cases, ANs and CFs categorized the educational value of HMAR as “helpful.”

#### HMAR for CEA

The use of AR for CEA has never been described. We performed 3 HMAR-assisted CEAs. First, the precise location of the internal carotid artery stenosis and the relevant anatomical landmarks (common carotid artery, carotid bifurcation, external carotid artery, sternocleidomastoid muscle, mylohyoid/omohyoid muscles, trachea, and esophagus) were identified with the hologram image. Although, registration had to be performed with the neck rotated, which modifies the position of some structures. AR offered significant educational value in identifying critical anatomical relationships and guiding the precise location of the skin incision (Figure 6). In these cases, ANs and CFs categorized the educational value of HMAR as “very helpful.”

#### Dyna Computed Tomography Integrated to HMAR

Dyna CTA is gaining popularity in the cerebrovascular discipline due to its high resolution and excellent bone-blood vessel demonstration after image postprocessing. It has been used as image guidance for several purposes, including the following: identification of AVMs during surgery,<sup>23</sup> evaluation and study of the central retinal artery,<sup>24</sup> assessment of venous vasculature,<sup>25</sup> and identification of fistulous points in DAVFs.<sup>26</sup> Thus far, Dyna



**Figure 6.** Case 25. The patient underwent a left CEA. (A) Hologram image of the AR platform using CTA of the head and neck. (B) Operating room view through the HoloLens 2 showing the hologram image matched to the head and neck of the patient in the neutral

position. Hologram registration was done with point-matching. The site of stenosis is at the origin of the left internal carotid artery (yellow circles). CEA, carotid endarterectomy; CTA, computed tomography angiogram.

CTA has not been described in combination with AR technology. However, we found that this imaging modality is very useful in the AR analysis of AVMs and DAVFs due to the high-definition visualization of medium and small-sized vessels.

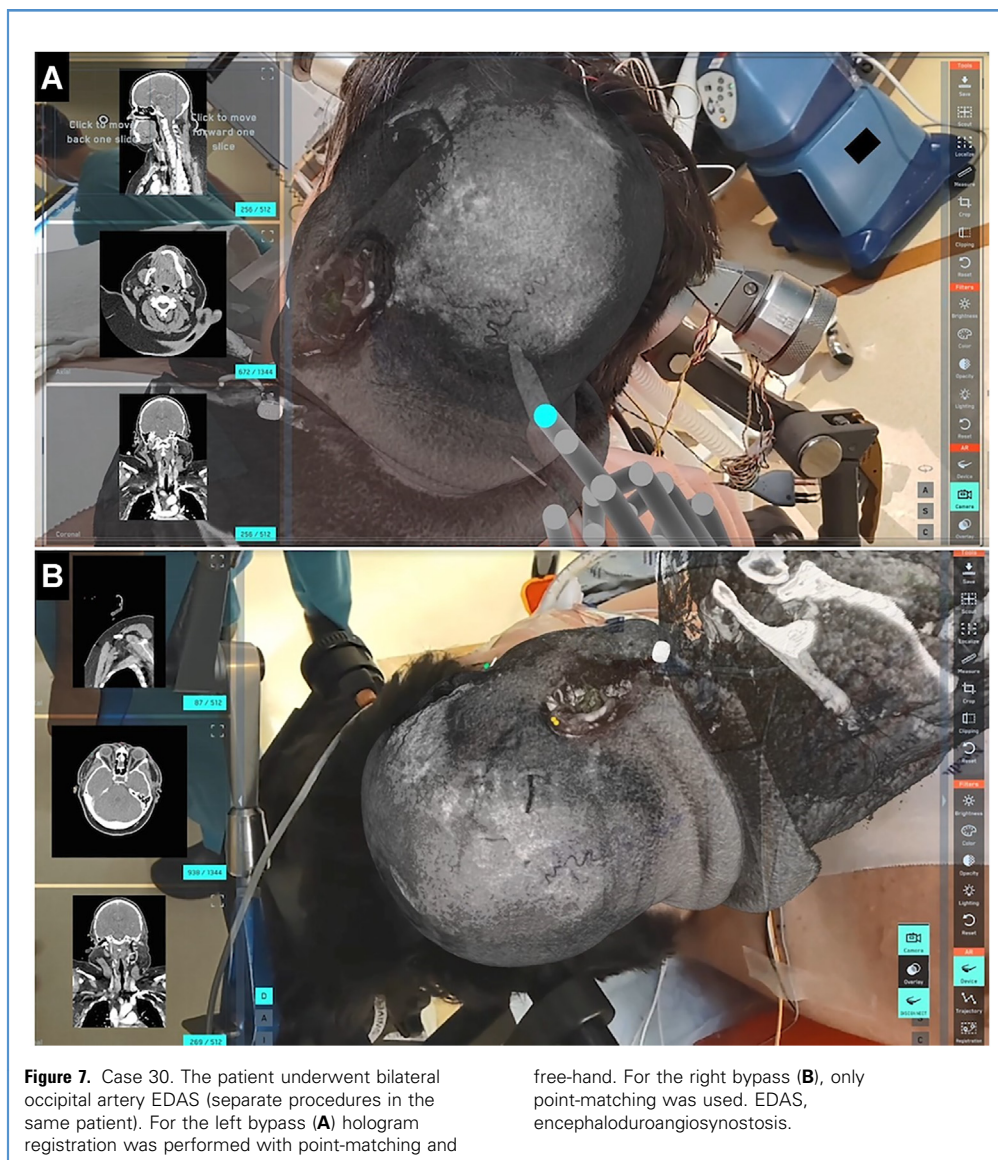
#### HMAR and Remote Proctoring

AR technology has shown promising results for surgical proctoring from remote locations.<sup>27,28</sup> The AR platform we used can be accessed by remote connection with Microsoft Teams (Microsoft, Redmond, WA). After connecting, the proctoring neurosurgeon can have a live transmission of the audio and view of the operating surgeon through the HoloLens 2. In our experience, this was successfully achieved. Further well-designed

studies are needed to define the role of remote proctoring in neurosurgical procedures.

#### Disadvantages of the AR System

The HoloLens 2 HM has a short battery life that limits the detailed study of the holographic images (especially in complex cases that require more time). The total operative time increases by a median of 10.5 minutes compared to the 6.2 minutes of the standard Stealth navigation system. The HMAR system has a learning curve and setting requirements that include the connection of the AR platform to the hospital system (available at different locations), hardware set-ups, software optimization, imaging processing, and registration of the hologram image to the patient (free hand and/or holographic-point matching). Also, after hologram matching,



the patient position cannot be adjusted because the hologram image is fixed to space rather than the patient. Of note, the latest version has improved the process of hologram matching by adding a skin tile as a fiducial point that allows continuous fusion even with movement. Future improvements such as surface matching and automatic registration can prompt the routine incorporation of this imaging tool into the surgical workflow.

### Limitations

The current study is vulnerable to biases inherent to retrospective analyses and is limited by the small sample size. In addition, the accuracy of the HMAR navigation was not systematically compared to the standard of Stealth neuronavigation. However, the goal of this study was not to use the AR system for surgical navigation but

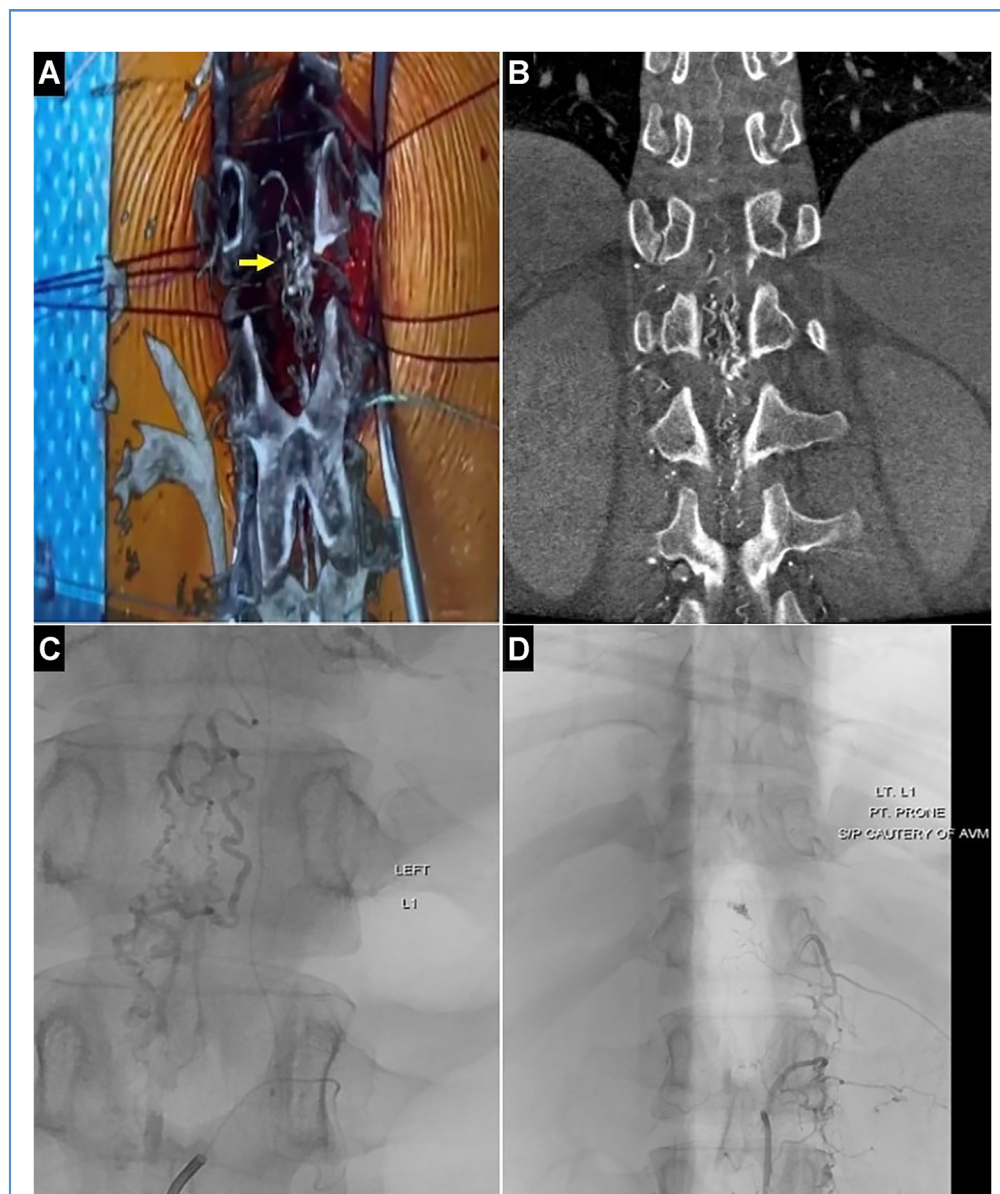
to evaluate how the surgical strategy and planning can be potentially influenced by its usage and to describe its role as an educational tool.

### CONCLUSION

HMAR technology in cerebrovascular neurosurgery provides educational value, enables a 3D understanding of complex vascular anatomy and can potentially optimize surgical strategies. However, further research is needed to confirm its clinical utility and reliability.

### CRediT AUTHORSHIP CONTRIBUTION STATEMENT

**Matias Costa:** Conceptualization, Methodology, Formal analysis, Investigation, Data curation, Writing – original draft, Writing –



**Figure 8.** Case 32. The patient underwent resection of a conus medullaris AVM at T12 – L1 level. **(A)** Posterior approach view showing the laminectomy with the hologram image in position over the open surgical field with the pathology in sight (yellow arrow). **(B)** Coronal view of the Dyna CTA depicting the

AVM. **(C)** Preoperative diagnostic spinal angiogram showing the AVM. **(D)** Intraoperative angiogram with the patient in prone position showing complete resection of the AVM with preservation of the left L1 radicular artery. AVM, arteriovenous malformation; CTA, computed tomography angiogram.

review & editing, Supervision, Project administration. **Clifford Pierre:** Formal analysis, Investigation, Resources, Data curation, Writing – original draft, Writing – review & editing. **Juan Vivanco-Suarez:** Validation, Formal analysis, Data curation, Writing – review & editing, Visualization. **Matias Baldoncini:** Validation, Writing – review & editing, Visualization. **Zane**

**Tymchak:** Writing – review & editing, Visualization, Supervision, Project administration. **Akshal Patel:** Writing – review & editing, Visualization, Supervision, Project administration. **Stephen J. Monteith:** Conceptualization, Methodology, Formal analysis, Investigation, Data curation, Writing – original draft, Writing – review & editing, Supervision, Project administration.

## REFERENCES

1. Bernardo A. Virtual reality and simulation in neurosurgical training. *World Neurosurg.* 2017;106:1015-1029.
2. Cho J, Rahimpour S, Cutler A, Goodwin CR, Lad SP, Codd P. Enhancing reality: a systematic review of augmented reality in neuronavigation and education. *World Neurosurg.* 2020;139:186-195.
3. Cannizzaro D, Zaed I, Safa A, et al. Augmented reality in neurosurgery, state of art and future projections. A systematic review. *Front Surg.* 2022; 9:864792.
4. Mascitelli JR, Bederson JB. In reply: navigation-linked heads-up display in intracranial surgery: early experience. *Oper Neurosurg (Hagerstown).* 2018; 14:E73.
5. Yoon JW, Chen RE, Kim EJ, et al. Augmented reality for the surgeon: systematic review. *Int J Med Robot.* 2018;14:e1914.
6. Paul P, Fleig O, Jannin P. Augmented virtuality based on stereoscopic reconstruction in multimodal image-guided neurosurgery: methods and performance evaluation. *IEEE Trans Med Imaging.* 2005;24:1500-1511.
7. Stadie AT, Reisch R, Kockro RA, et al. Minimally invasive cerebral cavernoma surgery using keyhole approaches - solutions for technique-related limitations. *Minim Invasive Neurosurg.* 2009;52:9-16.
8. Cabrilo I, Schaller K, Bijlenga P. Augmented reality-assisted bypass surgery: embracing minimal invasiveness. *World Neurosurg.* 2015;83:596-602.
9. Cabrilo I, Bijlenga P, Schaller K. Augmented reality in the surgery of cerebral arteriovenous malformations: technique assessment and considerations. *Acta Neurochir.* 2014;156:1769-1774.
10. Cabrilo I, Bijlenga P, Schaller K. Augmented reality in the surgery of cerebral aneurysms: a technical report. *Neurosurgery.* 2014;110(Suppl 2):252-260 [discussion: 260-261].
11. Toyooka T, Otani N, Wada K, et al. Head-up display may facilitate safe keyhole surgery for cerebral aneurysm clipping. *J Neurosurg.* 2018;129:883-889.
12. Carl B, Bopp M, Benescu A, Saß B, Nimsky C. Indocyanine green angiography visualized by augmented reality in aneurysm surgery. *World Neurosurg.* 2020;142:e307-e315.
13. Fierstra J, Anon J, Mendelowitsch I, et al. Amended intraoperative neuronavigation: three-dimensional vascular roadmapping with selective rotational digital subtraction angiography. *World Neurosurg.* 2020;135:183-187.
14. Rychen J, Goldberg J, Raabe A, Bervini D. Augmented reality in superficial temporal artery to middle cerebral artery bypass surgery: technical note. *Oper Neurosurg (Hagerstown).* 2020;18:444-450.
15. Carl B, Bopp M, Chehab S, Bien S, Nimsky C. Preoperative 3-dimensional angiography data and intraoperative real-time vascular data integrated in microscope-based navigation by automatic patient registration applying intraoperative computed tomography. *World Neurosurg.* 2018;113:e414-e425.
16. King AP, Edwards PJ, Maurer CR Jr, et al. A system for microscope-assisted guided interventions. *Stereotact Funct Neurosurg.* 1999;72:107-111.
17. Agha RA, Sohrabi C, Mathew G, et al. The PROCESS 2020 guideline: updating consensus preferred reporting of CasE Series in surgery (PROCESS) guidelines. *Int J Surg.* 2020;84:231-235.
18. Kockro RA, Tsai YT, Ng I, et al. Dex-ray: augmented reality neurosurgical navigation with a handheld video probe. *Neurosurgery.* 2009;65:795-807 [discussion: 807-808].
19. Ivan ME, Eichberg DG, Di L, et al. Augmented reality head-mounted display-based incision planning in cranial neurosurgery: a prospective pilot study. *Neurosurg Focus.* 2021;51:E3.
20. Kersten-Oertel M, Gerard I, Drouin S, et al. Augmented reality in neurovascular surgery: feasibility and first uses in the operating room. *Int J Comput Assist Radiol Surg.* 2015;10:1823-1836.
21. Aguilar-Salinas P, Gutierrez-Aguirre SF, Avila MJ, Nakaji P. Current status of augmented reality in cerebrovascular surgery: a systematic review. *Neurosurg Rev.* 2022;45:1951-1964.
22. Davids J, Manivannan S, Darzi A, Giannarou S, Ashrafian H, Marcus HJ. Simulation for skills training in neurosurgery: a systematic review, meta-analysis, and analysis of progressive scholarly acceptance. *Neurosurg Rev.* 2021;44:1853-1867.
23. Srinivasan VM, Schafer S, Ghali MG, Arthur A, Duckworth EA. Cone-beam CT angiography (Dyna CT) for intraoperative localization of cerebral arteriovenous malformations. *J Neurointerv Surg.* 2016;8:69-74.
24. Raz E, Shapiro M, Shepherd TM, et al. Central retinal artery visualization with cone-beam CT angiography. *Radiology.* 2022;302:419-424.
25. Srinivasan VM, Chintalapani G, Duckworth EAM, Kan P. Advanced cone-beam CT venous angiographic imaging. *J Neurosurg.* 2018;129:114-120.
26. Hiu T, Kitagawa N, Morikawa M, et al. Efficacy of DynaCT digital angiography in the detection of the fistulous point of dural arteriovenous fistulas. *AJNR Am J Neuroradiol.* 2009;30:487-491.
27. Shenai MB, Tubbs RS, Guthrie BL, Cohen-Gadol AA. Virtual interactive presence for real-time, long-distance surgical collaboration during complex microsurgical procedures. *J Neurosurg.* 2014;121:277-284.
28. Shenai MB, Dillavou M, Shum C, et al. Virtual interactive presence and augmented reality (VIPAR) for remote surgical assistance. *Neurosurgery.* 2011;68(1 Suppl Operative):200-207 [discussion: 207].

*Conflict of interest statement: The authors declare that the article content was composed in the absence of any commercial or financial relationships that could be construed as a potential conflict of interest.*

Received 28 October 2022; accepted 19 December 2022

Citation: *World Neurosurg.* (2023).

<https://doi.org/10.1016/j.wneu.2022.12.086>

Journal homepage: [www.journals.elsevier.com/world-neurosurgery](http://www.journals.elsevier.com/world-neurosurgery)

Available online: [www.sciencedirect.com](http://www.sciencedirect.com)

1878-8750/\$ - see front matter © 2022 Elsevier Inc. All rights reserved.